

Age Estimation From Stages of Union of the Vertebral Epiphyses of the Ribs

Luis Ríos^{1*} and Hugo F.V. Cardoso^{2,3}

¹*Comisión Docente de Antropología, Departamento de Biología, Facultad de Ciencias, Universidad Autónoma de Madrid, Madrid 28049*

²*Departamento de Zoología e Antropologia (Museu Bocage), Museu Nacional de História Natural and Centro de Biologia Ambiental, Lisboa, Portugal*

³*Faculdade de Medicina, Universidade do Porto, Porto, Portugal*

KEY WORDS skeletal age; rib maturation; Lisbon collection; fluctuating asymmetry

ABSTRACT This study attempts to fill a persistent gap in the literature by documenting the timing of epiphyseal union at the vertebral end of the ribs in a sample of modern Portuguese skeletons. The skeletal remains of 53 females and 45 males, between the ages of 11 and 30, were taken from the Lisbon documented skeletal collection. Individuals in the sample have been previously described as being representative of a middle-to-low socioeconomic segment of the early 20th century Lisbon population. Three anatomical locations were examined for epiphyseal union: the head, the articular tubercle and the nonarticular tubercle. The first epiphysis to show partial union is that of the nonarticular tubercle (females, 11–19 years; males, 11–19 years),

followed by the epiphysis of the articular tubercle (females, 11–20 years; males, 16–20 years), and finally by the head epiphysis (females, 15–24 years; males, 16–22 years), which can still show incomplete epiphyseal closure at 25 and 24 years for females and males, respectively. A trend for earlier female maturation was observed, but the statistical tests only confirmed this result for some ribs and age groups. No directional asymmetry was found, but a significant fluctuating asymmetry was observed in all three epiphyses. A preliminary analysis showed that the asymmetric group of individuals in the study sample includes all the rural-to-urban migrants, relative to the symmetric group. *Am J Phys Anthropol* 000:000–000, 2009. © 2009 Wiley-Liss, Inc.

Age estimation is one of the basic steps in the study of human skeletal remains, whether in archaeological or forensic contexts (Iscan, 1989; Mays, 1998; Hoppa and Vaupel, 2002; Byers, 2005; Schmeling et al., 2007). In pubertal and young adult skeletons, the observation and scoring of epiphyseal activity can be considered a simple and reliable method for age estimation because of the easiness in scoring and to the narrow age ranges associated with epiphyseal union stages, especially when compared with other macroscopic methods utilized in adults, which are more subjective and include more complex scoring systems (Kimmerle et al., 2008), as well as wider age ranges (Martrille et al., 2007; Wittwer-Backofen et al., 2008). Besides the seminal work of McKern and Stewart (1957), in the last few years, different studies have documented the age ranges of epiphyseal closure in geographic and temporally diverse skeletal samples, such as the Italian series from Bologna, Sassari, and Cagliari (Veschi and Facchini, 2002), the contemporary Bosnian forensic sample (Schaefer and Black, 2005), and the modern Portuguese collections from Coimbra (Coqueugniot and Weaver, 2007) and from Lisbon (Cardoso, 2008a,b). In these studies, maturation data can be found for a long and diverse list of epiphyses from the axial and appendicular skeleton. However, some bones that mature between puberty and the first years of the third decade of life have not been included in these works, and among them are the ribs. The changes in the sternal end of the fourth rib have been studied in diverse samples as a method for adult age estimation (Iscan et al., 1984; Iscan et al., 1985; Loth, 1995; Yavuz et al., 1998; Oettlé and Steyn, 2000), and more recently

the morphological changes of the adult first rib have been another focus of research (Kunos et al., 1999; Schmitt and Murail, 2004; Kurki, 2005; DiGangi et al., 2009). However, the secondary centers of ossification of the ribs have received less attention, and research on these epiphyses only includes the early note of Fawcett (1911), the works of Stevenson (1924), Hodges (1933), McKern and Stewart (1957), Kunos et al. (1999), and some clinical oriented articles (e.g. Hoppenfeld et al., 2004), most of them centered in the head epiphysis.

As indicated by Fawcett (1911), in early anatomy textbooks three epiphyses were described in the proximal rib, located at the head, articular tubercle and nonarticular tubercle. Through the study of the ribs of an 18-year-old male morgue specimen, Fawcett (1911) summarized the observations carried out until that time with regard to the presence and degree of fusion of these epiphyses. From his revision of the literature, Fawcett (1911) stated that complete fusion of the head epiphysis

Grant sponsor: Fundação para a Ciência e Tecnologia; Grant number: SFRH/BPD/22142/2005.

*Correspondence to: Luis Ríos, Comisión Docente de Antropología, Departamento de Biología, Facultad de Ciencias, Universidad Autónoma de Madrid, Madrid 28049. E-mail: luis.rios@uam.es

Received 28 October 2008; accepted 6 February 2009

DOI 10.1002/ajpa.21065

Published online in Wiley InterScience (www.interscience.wiley.com).

is achieved by 25 years. Some years later, Stevenson (1924) found difficulties in interpreting the maturation pattern at the tubercle epiphyses, and stated that the “epiphysis for the tubercle fuses as it ossifies, so that a completely ossified though ununited epiphysis is very rarely seen” (Stevenson, 1924: 73). This author described the tubercle epiphyses as fusing in most cases in the 18th year and the head epiphysis as completely fused in all cases after the 22nd year. In his study, however, Stevenson (1924) did not discriminate between the sexes and between ribs. According to Hodges (1933), the rib epiphyses fuse between 17 and 21 years of age, but this author did not distinguish between the head and tubercle epiphyses and between the ribs. In a more systematic study, McKern and Stewart (1957) stated that their military male data “point to a probable age of 17 years for first appearance of complete union of the head epiphyses and a definite age of 24 years for the stage when all ribs are mature in all cases” (McKern and Stewart, 1957: 160). With respect to the epiphyses for the tubercles they stated that “The epiphyses for the tubercles were not recorded because of the difficulty of interpreting their status of union; they are among the smallest in the skeleton and their appearance is much the same before and after union” (McKern and Stewart, 1957: 157). Kunos et al. (1999) discuss the maturation of the epiphyses from the head and articular tubercle of the first rib in a sample from the Hamann-Todd collection. For the head epiphyses, the earliest age at complete fusion was 18 years, and the oldest individual with an unfused epiphysis was 21 years. With regard to the articular tubercle epiphyses, the earliest age at complete fusion was 17 years, and the oldest individual with an unfused epiphysis was 19 years. Female maturation data, in comparison, is scarce, but if we take Hoppenfeld et al.’s (2004) radiographic age range of closure at each growth center as the age interval at which the epiphysis is fusing, the epiphysis of the head fuses between 15.3 and 19.0 years in females and 15.6 and 19.8 in males. However, Hoppenfeld et al.’s (2004) research, as well as the aforementioned work of Hodges (1933), are radiographic studies, and age ranges may not be equivalent to those obtained from studies of dry-bone, as it has been observed that the method of observation can have a significant impact on age estimation (for a specific study on the clavicle see Meijerman et al., 2007).

Therefore, there is a persistent gap in the literature about the epiphyseal union pattern of the vertebral end of the ribs. Even McKern and Stewart’s (1957) study only provides data for the head epiphysis and for males, and their sample is truncated at age 17. The main purpose of this study is to document the sex and age variation in epiphyseal union of the head, articular, and nonarticular tubercle in all 12 ribs, using the Lisbon documented skeletal sample. In addition, we also wish to examine the frequency of presence/absence of the articular and nonarticular tubercles, the bilateral asymmetry in epiphyseal union at all locations and finally, tentatively explore the association of cause of death and socioeconomic status to the individual’s asymmetry in fusion.

MATERIALS AND METHODS

Sample description

The skeletal remains of 98 individuals of known sex and age at death were selected from the Lisbon identified skeletal collection (Cardoso, 2006) and comprise this

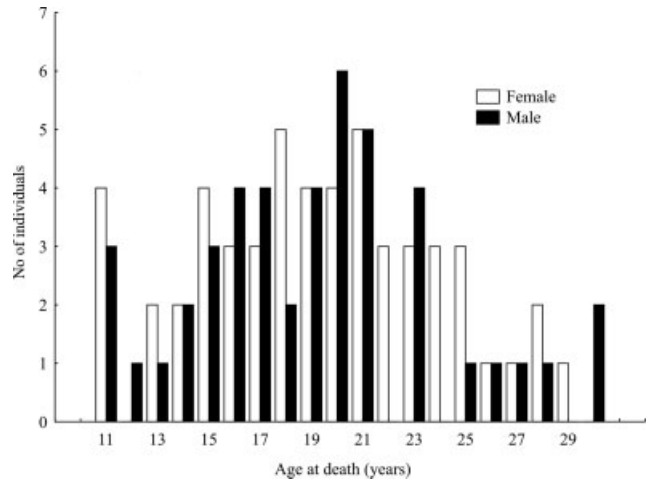


Fig. 1. Sex and age distribution of the sample.

study’s sample. The skeletal remains represent middle to low social class individuals, who lived in the city of Lisbon at the time of their death. Most individuals in this study sample were born between 1920 and 1930 and years of birth range from 1887 to 1960. Years of death range from 1903 to 1975, with most deaths occurring between 1940 and 1950. Individuals in this sample have also been utilized in previous studies (Cardoso, 2008a,b; Ríos et al., 2008), but samples do not overlap entirely. Individuals’ ages range from 11 to 30 years and females are only slightly more numerous than males (females, 53; males, 45). Observations of epiphyseal union during the data collection process established the upper and lower age limits and the sample includes all observable individuals in the collection between 11 and 30 years of age. Exact calendar age was obtained from birth and death civil records and assessment of accuracy in reported ages at death has been described in greater detail in Cardoso (2005). The age and sex distribution of the sample is depicted in Figure 1.

Anatomical description and scoring system

The functional anatomy of the proximal rib is described in detail in standard anatomy textbooks (e.g. Standring, 2005) and some research articles (Ibrahim and Darwish, 2005). Briefly, the ribs are connected to the vertebral column by the costovertebral joints, where the head of the rib articulates with the lateral facet of the vertebral body, and the stability is maintained by the radiate and intra-articular ligaments. Comparatively, the articular tubercle of the rib articulates with the facet of the transverse process of the vertebra and the stability is maintained by the costotransverse ligaments, which bind the costal necks and the articular and nonarticular tubercles to the transverse process of the vertebra (for details on dissection specimens see Ibrahim and Darwish, 2005). Lower ribs do not possess tubercles as they do not articulate with the transverse processes of the vertebrae, so that the presence of the tubercles depends on the rib number (Fawcett, 1911; Scheuer and Black, 2000). Therefore, in the ribs, epiphyses are found at three locations: the head, the tubercle, and the nonarticular tubercle, as indicated in Figure 2.

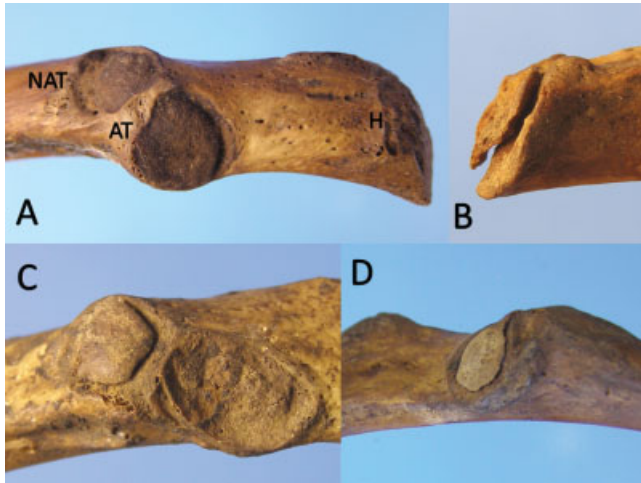


Fig. 2. **A:** location of the head (H), articular tubercle (AT), and nonarticular tubercle (NAT) in the fifth left rib of a 15-year-old male, the three locations are in Stage 1 or absence of fusion. **B:** Stage 2 in the head of the tenth right rib of a 17-year-old male. **C:** Stage 2 in the nonarticular tubercle of the fifth left rib of a 17-year-old male. **D:** Stage 2 in the articular tubercle of the seventh right rib of a 16-year-old female. [Color figure can be viewed in the online issue, which is available at www.interscience.wiley.com.]

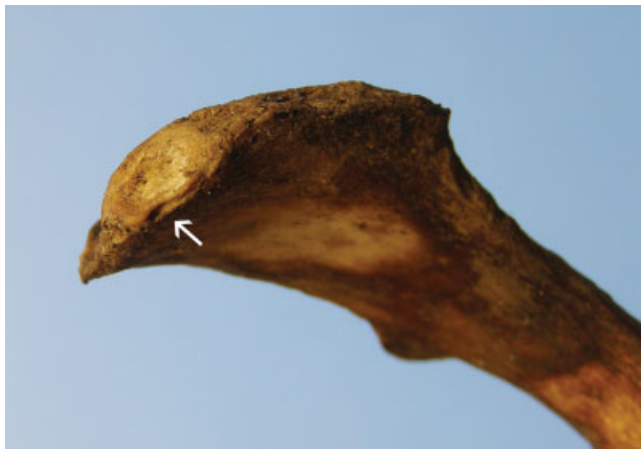

Fig. 3. Epiphyseal scar on the head of a rib from a 47-year-old male from the Lisbon collection. [Color figure can be viewed in the online issue, which is available at www.interscience.wiley.com.]

Before scoring the degree of epiphyseal fusion, the first step was to determine rib side and number by seriating the ribs, following visual criteria extracted from the recommendations of diverse authors (Dudar, 1993; Mann, 1993; Hoppa and Saunders, 1998; Owers and Pastor, 2005). Then, on each rib we scored the presence or absence of the articular and nonarticular tubercle in order to obtain the frequency of these anatomical landmarks. Next, we scored the degree of fusion of the epiphyses following a three stage scale: (1) no union; (2) partial union; (3) completed union (see Fig. 2 for illustrations). This scheme was chosen because successive stages would be only marginally different, if more than three stages were considered, and this reduces the imprecision when



Fig. 4. Stage 2b in the head of the tenth ribs of a 25-year-old female. Observe that fusion in the perimeter is completed while in the middle of both heads an open area of bone with traces of only partial union can be seen. [Color figure can be viewed in the online issue, which is available at www.interscience.wiley.com.]

scoring in repeated observations. As explained elsewhere (Cardoso, 2008a), one seemingly important problem in recording stages of epiphyseal union is the epiphyseal line or scar in the metaphyseal perimeter. This gapless line, which can persist at the diaphyseal–epiphyseal junction sometime after complete union, must not be mistaken for partial union at the risk of overestimating age of fusion (Stevenson, 1924). In the authors' experience, this epiphyseal scar can persist several years after complete union. In effect, this persistence was confirmed by preliminary observations of the head epiphysis in older adults (40- to 50-year-old) from the collection (see Fig. 3). Therefore, when a scar was present we scored it as 3 (complete union) unless we were able to observe an empty space without bone filling the space underneath the growing epiphysis. After preliminary inspection of the ribs, it was decided to include an additional stage of maturation for the head epiphysis only. This new stage (designated 2b), only applies to observations where the head epiphysis is completely fused in the periphery, around the diaphyseal–epiphyseal junction, but an area of only partial union can be observed at the center of the epiphysis (illustrated in Fig. 4). Therefore, the main distinction between stage 2 and stage 2b in the head epiphysis is that, whereas in stage 2 the partial union is observed in the periphery, in stage 2b it is only observed centrally. Although this new stage has been defined as 2b, it does not imply sequence in the process of epiphyseal union relative to stage 2, since no description of such a stage has been found in the literature, neither its relation to the ossification sequence.

For every skeleton, only identified ribs in terms of number and side were scored, and every rib was considered independent (e.g., first left and first right ribs from the same skeleton were scored independently). Both authors repeated the assessments on all ribs of four individuals after an interval of a few days in order to provide an estimate of intraobserver agreement. The first assessments of each observer were also compared with that of the other observer so as to offer a measure of

TABLE 1. Intra and interobserver error results for the three epiphyses of the vertebral end of the ribs, assessed by percentage of agreement

Epiphyses	Intraobserver agreement		Interobserver agreement
	Observer 1 (%)	Observer 2 (%)	Observer 1 versus Observer 2 (%)
Head	93	92	81
Articular tubercle	81	95	84
Nonarticular tubercle	69	85	91

TABLE 2. Presence/absence of the articular tubercle (sexes combined)

Rib number	1	2	3	4	5	6	7	8	9	10	11	12
<i>N</i>	153	181	191	189	183	177	177	176	175	168	178	134
Presence %	100	100	100	100	100	100	100	99	91	46	5	–
Absence %	–	–	–	–	–	–	–	1	9	54	95	100

interobserver agreement. Percentage of agreement was calculated to measure observer concordance.

Sex differences and bilateral asymmetry

To assess possible sexual differences in maturation, we divided the sample in three age groups and applied the nonparametric Mann-Whitney and Chi-square tests, to test if the distribution of the ordinal variable stage of fusion presented significant differences between males and females. We considered three age groups due to the different age ranges for fusion of the three epiphyses (see in the following text). The first age group (11- to 16-year-old) represents approximately the range of beginning of fusion for the tubercle epiphyses and absence of fusion for the head epiphyses; the second age group (17 to 20-year-old) represents approximately the range of active fusion for the three epiphyses; and the third age group (21 to 25-year-old) represents the range of active fusion for the head and complete fusion for the tubercles in most cases. We are conscious that the age grouping is somewhat arbitrary, and that this decision would affect the sample sizes and age distributions and, therefore, the results of the statistical tests. Therefore, we repeated the tests with slightly different age groups, and compared these results with those obtained with the earlier groups.

Because of previous findings regarding the possible importance of asymmetry in the degree of fusion in bilateral epiphyses, as indicative of environmental stress (Albert and Greene, 1999), a separate record was kept for left and right ribs. We wanted to know if there was any asymmetry in fusion and if there was directionality in the asymmetry. For each epiphysis, three variables were created. One variable was created for right-side epiphyseal union (ASR), and another for left-side epiphyseal union (ASL). These variables are defined as the sum of the epiphyseal stages' scores of all the available epiphyses for each side, with the condition of bilateral presence for each rib number included and more than eight pairs of observable ribs present by skeleton. Two different statistical tests were applied to these two variables to determine the presence of a significant directional asymmetry. The Wilcoxon nonparametric test was used to determine the presence of a significant difference between ASR and ASL. This test evaluates if the amount of the difference between the right and left sides is statistically significant. Sign tests were also used to assess whether the asymmetry favored one of the sides. Even if

directional asymmetry was not detected, by either the Wilcoxon or Sign tests, the individuals could still show several ribs with alternating side asymmetry. Therefore, a third variable was created: the total score of asymmetry (AST). This variable was defined as the sum of the absolute values of the differences in fusion between asymmetrical ribs for each skeleton. The distribution of AST values was compared with the Poisson distribution to assess whether asymmetric cases were just rare events in comparison with symmetric cases (AST = 0). The Kolmogorov-Smirnov test was used to assess the goodness of fit.

RESULTS

Intra- and inter-observer agreement tests are shown in Table 1. Results reveal that observer agreement is fairly good and in only four occasions is the percent agreement under 85%. Observer 2 shows slightly overall higher intra-agreement, and interobserver agreement is lower than intraobserver agreement, except for the non-articular tubercle epiphysis. The head epiphysis shows the highest intraobserver agreement, whereas it is the nonarticular tubercle which shows the highest interobserver agreement.

No sex differences were observed in the presence/absence of the articular tubercle. Its presence was observed in all available ribs from the first to the seventh, with decreasing frequency from the eight (99%) to the eleventh (5%), and it was not observed in the twelfth rib (Table 2). With regard to the nonarticular tubercle, no sex differences were also observed in presence/absence. Its presence was observed with increasing frequency from the first to the sixth rib, and with decreasing frequency from the seventh (82%) to the eleventh (4%) rib, and it was also not observed in the twelfth rib (Table 3).

With regard to the presence of bilateral asymmetry in the degree of fusion, Tables 4 and 5 show the number and percentage of type of asymmetry, and the number and percentage of asymmetric cases by epiphyses and rib number, respectively. The Wilcoxon test did not find any significant difference between ASR and ASL for the three epiphyses (head, $P = 0.507$; articular tubercle, $P = 0.406$; nonarticular tubercle, $P = 0.317$). All Sign tests were also statistically insignificant. Therefore, the asymmetry in epiphyseal union is not predominantly associated with one of the sides, i.e., there is no directional asymmetry. Conversely, the Kolmogorov-Smirnov test showed that the study sample did not fit a Poisson dis-

TABLE 3. Presence/absence of the nonarticular tubercle (sexes combined)

Rib number	1	2	3	4	5	6	7	8	9	10	11	12
N	152	181	190	188	182	173	173	176	174	168	178	134
Presence %	57	87	94	98	98	95	82	52	24	12	4	—
Absence %	43	13	6	2	2	5	18	48	76	88	96	100

TABLE 4. Percentage and number of symmetrical and asymmetrical cases, and types of asymmetry

Type of asymmetry	% (N)
Symmetrical	30.6 (30)
Asymmetrical	69.1 (68)
Asymmetry at the head	41.8 (41)
Asymmetry at the tubercle	5.1 (5)
Asymmetry at the nonarticular tubercle	9.1 (9)
Asymmetry at the head and tubercle	3.0 (3)
Asymmetry at the head and nonarticular tubercle	3.0 (3)
Asymmetry at both tubercles	5.1 (5)
Asymmetry at the three epiphyses	2 (2)

tribution thus indicating that the presence of asymmetrical cases is not a rare and random event in each of the three epiphyses (head, $P = 0.000$; articular tubercle, $P = 0.000$; nonarticular tubercle, $P = 0.000$). This confirms the presence of fluctuating asymmetry in the stage of fusion of all the epiphyses.

The age ranges for the different degrees of fusion by sex in each epiphysis are summarized in Tables 6–8. Because of the presence of statistically significant non-directional asymmetry and in order to fully capture the age variability in degree of fusion, the sample sizes used to elaborate these tables do not refer to the number of skeletons but rather to the number of observable ribs: one skeleton can contribute with the right and left first rib if both are preserved, and the rationale for this choice is that in many cases both ribs differ in the state of maturation (i.e., there is asymmetry in the state of fusion). The first epiphysis to show partial union is that of the nonarticular tubercle (females, 11–19 years; males, 11–19 years), followed by the epiphysis of the articular tubercle (females, 11–20 years; males, 16–20 years), and finally by the head epiphysis (females, 15–24 years; males, 16–22 years), which still can show epiphyseal activity in the center (Stage 2b) at 25 and 24 years for females and males, respectively. The percentages of complete fusion (Stage 3) by age and rib number for the head epiphysis are shown in Table 9. It can be observed that there is a general trend toward an earlier fusion of the first and last ribs in comparison with the central ribs for this epiphysis. The other two epiphyses share the same overall pattern.

The results of the Chi-square and the Mann-Whitney tests, for assessing sex differences in maturation, can be seen in Tables 10–12. The Mann-Whitney test detected significant differences in four ribs and in two of the age groups for the head epiphyses, in seven ribs and in two of the age groups for the articular tubercle epiphysis, and in seven ribs and also in two of the age groups for the nonarticular epiphysis. The Chi-square test only confirmed these differences for one rib for the head epiphysis, one rib for the articular tubercle epiphysis, and five ribs for the nonarticular epiphysis, although in most cases the P values were close to the 0.05 significance level. The results only changed slightly when we used a different age categorization (variation of the upper and

TABLE 5. Percentages and number (in brackets) of asymmetrical cases by epiphyses and rib number (in relation to the cases with observable pairs of ribs)

Rib number	Head	Articular tubercle	Nonarticular tubercle
1	15.7 (11)	3.1 (2)	0 (0)
2	15.2 (12)	6 (5)	7.5 (5)
3	9.2 (8)	5.5 (5)	2.4 (2)
4	16 (14)	5.5 (5)	3.3 (3)
5	14.3 (12)	8.2 (7)	7.2 (6)
6	17.9 (14)	2.6 (2)	6.7 (6)
7	14.8 (12)	4.8 (4)	7.2 (4)
8	13.6 (11)	10.2 (8)	8.4 (3)
9	18.5 (14)	7 (5)	—
10	16.9 (12)	4.2 (1)	—
11	19.5 (16)	—	—
12	10.5 (5)	—	—
TOTAL	50 (49)	15.3 (15)	19.4 (19)

In the last row the percentage and frequency of asymmetrical skeletons in relation to the total sample by epiphyses.

lower age limits by 1–2 years for every age group). In all the cases, the difference was toward a trend in earlier maturation of the female sample.

DISCUSSION

This study wished to document age, sex, and side variation in rib maturation, and a proper discussion of the results should begin with some observations on observer concordance. Most errors in intra and interobserver comparisons in the articular and nonarticular tubercle result from a nonunited (Stage 1) epiphysis being mistaken for an united (Stage 3) epiphysis and vice-versa. Also, in some occasions, a united nonarticular epiphysis was mistaken for an absent epiphysis or, more rarely, a non-united nonarticular epiphysis mistaken by an absent epiphysis. In the interobserver test, this confusion could be due to misidentification of rib number for consecutive ribs. This indicates that reliable information about bone maturation for use in age estimation is better obtained from the observation of partial union (Stage 2). In the head, there were some occasions where cases were scored as fused by one observer and partially fused by the other observer. After reviewing these cases it was found that it was the epiphyseal scar which sometimes misled some of the classifications. The observer error results reported here indicate that the state of fusion of the epiphyses of the head and tubercles can be recognized, but we agree with Stevenson's (1924) and McKern and Stewart's (1957) cautionary note that nonunited epiphyses of the tubercles simulates, with remarkable closeness, the appearance of the united epiphysis.

The observations on the presence or absence of the articular and nonarticular tubercles agree with findings and observations from previous authors (Fawcett, 1991; Scheuer and Black, 2000). The absence of the articular tubercle in the twelfth and eleventh (95%) ribs indicate the lack of articulation of those ribs with the transverse

TABLE 6. Summary of ages of union for the head epiphysis (ages are in years)

Rib number	Female				Male			
	Stage 1	Stage 2	Stage 2b	Stage 3	Stage 1	Stage 2	Stage 2b	Stage 3
1	≤19	15–20 (n = 15)	22 (n = 1)	≥18	≤21	16–20 (n = 12)	–	≥17
2	≤19	15–20 (n = 13)	–	≥18	≤21	17–21 (n = 14)	17 (n = 1)	≥17
3	≤19	15–24 (n = 19)	–	≥18	≤20	17–21 (n = 14)	–	≥17
4	≤19	15–24 (n = 27)	–	≥18	≤20	17–22 (n = 19)	–	≥19
5	≤19	15–21 (n = 30)	22–24 (n = 2)	≥18	≤21	17–22 (n = 21)	–	≥19
6	≤19	16–23 (n = 22)	18–23 (n = 5)	≥18	≤21	17–21 (n = 21)	–	≥19
7	≤20	17–24 (n = 29)	18–23 (n = 6)	≥18	≤21	17–20 (n = 15)	20 (n = 1)	≥19
8	≤19	17–21 (n = 23)	18–22 (n = 5)	≥18	≤21	16–22 (n = 17)	20 (n = 1)	≥19
9	≤19	15–24 (n = 26)	18–22 (n = 2)	≥18	≤20	17–22 (n = 16)	24 (n = 1)	≥19
10	≤23	15–24 (n = 14)	21–25 (n = 3)	≥18	≤21	16–22 (n = 21)	–	≥20
11	≤23	15–23 (n = 19)	20 (n = 1)	≥17	≤21	16–21 (n = 20)	20 (n = 1)	≥19
12	≤23	15–20 (n = 15)	22 (n = 1)	≥18	≤20	17–21 (n = 11)	–	≥19

TABLE 7. Summary of ages of union for the articular tubercle epiphysis (ages are in years)

Rib number	Female			Male		
	Stage 1	Stage 2	Stage 3	Stage 1	Stage 2	Stage 3
1	≤16	15 (n = 2)	≥14	≤18	16 (n = 1)	≥17
2	≤16	14–15 (n = 2)	≥14	≤19	18 (n = 1)	≥11
3	≤16	14–19 (n = 4)	≥14	≤19	18 (n = 1)	≥11
4	≤16	15–19 (n = 2)	≥14	≤19	16–18 (n = 4)	≥11
5	≤16	14–19 (n = 4)	≥14	≤19	17 (n = 3)	≥11
6	≤16	15–19 (n = 3)	≥15	≤19	17 (n = 2)	≥11
7	≤16	14–15 (n = 3)	≥15	≤19	16–17 (n = 2)	≥11
8	≤16	14–19 (n = 6)	≥15	≤19	16–20 (n = 3)	≥11
9	≤16	14–20 (n = 8)	≥15	≤19	–	≥16
10	≤16	11–15 (n = 3)	≥14	≤19	16 (n = 1)	≥12

TABLE 8. Summary of ages of union for the nonarticular tubercle epiphysis (ages are in years)

Rib number	Female			Male		
	Stage 1	Stage 2	Stage 3	Stage 1	Stage 2	Stage 3
1	≤13	15 (n = 1)	≥15	≤17	11 (n = 1)	≥16
2	≤16	13–16 (n = 3)	≥11	≤19	11–16 (n = 3)	≥12
3	≤15	13–16 (n = 6)	≥11	≤19	11–18 (n = 6)	≥16
4	≤15	13–16 (n = 6)	≥11	≤19	11–19 (n = 10)	≥16
5	≤16	13–16 (n = 4)	≥11	≤19	11–18 (n = 9)	≥12
6	≤15	11–19 (n = 7)	≥13	≤19	11–18 (n = 6)	≥16
7	≤16	11–16 (n = 6)	≥13	≤20	16–19 (n = 3)	≥11
8	≤16	14–19 (n = 3)	≥11	≤19	–	≥16

TABLE 9. Summary table for percentage of complete fusion at the head epiphysis for both sexes

Age (years)	Rib number											
	1	2	3	4	5	6	7	8	9	10	11	12
16	–	–	–	–	–	–	–	–	–	–	–	–
17	8	7	8	–	–	–	–	–	–	–	8	–
18	57	50	36	36	29	29	29	36	31	43	38	50
19	33	43	23	26	6	6	12	10	12	–	26	47
20	65	66	50	29	30	33	15	18	20	32	38	68
21	75	75	62	50	37	50	50	43	75	43	75	80
22	91	100	100	85	70	90	64	54	64	89	92	87
23	100	100	100	80	100	67	83	100	80	80	67	75
24	100	100	87	87	87	100	86	100	75	86	100	100
25	100	100	100	100	100	100	100	100	100	100	100	100
26	100	100	100	100	100	100	100	100	100	100	100	100

process of the vertebrae. This absence was also found in the tenth rib (54%). These observations parallel those found for the nonarticular tubercle at the twelfth (100%) and eleventh (96%) ribs, although the frequency of the nonarticular tubercle is lower for the tenth (88% ab-

sence), ninth (76% absence), and eight (48% absence) ribs in comparison with the articular tubercle. This fact can be observed also for the first (43%) and second rib (13%). In these ribs, these lower frequencies of the nonarticular tubercle can be explained by the fact that both

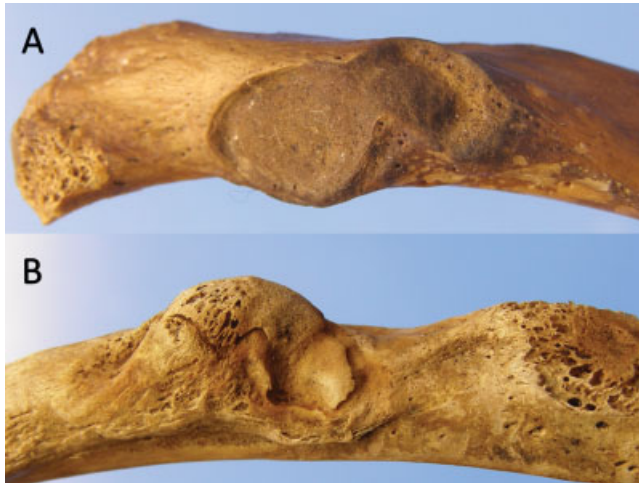

Fig. 5. **A:** The ninth right rib of a 15-year-old male. Observe that both tubercles, articular and nonarticular are not separated. **B:** The fourth left rib of a 18-year-old male. Observe that the nonarticular tubercle's epiphysis reaches the surface of the articular tubercle. [Color figure can be viewed in the online issue, which is available at www.interscience.wiley.com.]

tubercles are very close and in some cases they do not exist as separate entities, especially in very young skeletons (Fig. 5A). It is interesting to note that in some cases a common epiphysis for both tubercles was observed (Fig. 5B).

With regard to the utility of epiphyseal union at the vertebral end of the ribs for age estimation, the information summarized in Tables 6–8 indicates that the three epiphyses are useful for age estimation in pubertal and young adult skeletons. The results for the head epiphysis are comparable with those of McKern and Stewart (1957) and Kunos et al. (1999). The complete fusion of the head epiphysis of all ribs is achieved by 25 years of age. The oldest cases showing peripheral epiphyseal activity (Stage 2) are a 24-year-old female and a 22-year-old male, whilst the oldest cases of active epiphyseal activity in the center of the head (Stage 2b) are a 25-year-old female and a 24-year-old male. Kunos et al. (1999) stated that “the fusion of the epiphysis with the rib is a protracted process with an epiphyseal scar apparent until about 25 years. In the Hamann-Todd collection, the oldest individual with an incompletely remodeled epiphyseal scar was 28 years” (Kunos et al., 1999: 308), while the oldest cases we observed with active fusion in the first rib were 20 years for both males and females. This difference can be explained by our more conservative approach when an epiphyseal scar was observable, as we chose not to score these cases as active fusion.

As for the epiphyses of the tubercles, the only available comparative data is that of Kunos et al. (1999), and our observations produced similar results. We want to emphasize again that it is difficult to distinguish between absence of fusion and complete fusion at both locations (but see Fig. 2 for an unequivocal stage 1 at both tubercles), since the aspect of the tubercles before and after fusion is very similar. Furthermore, this confusion can include stage 2 (partial union) because it is not infrequent to find a bony spur resembling an epiphyseal flake growing over the articular and nonarticular tubercles. We have observed this bony spur in skeletons from different age ranges and both sexes, from 19 to 40

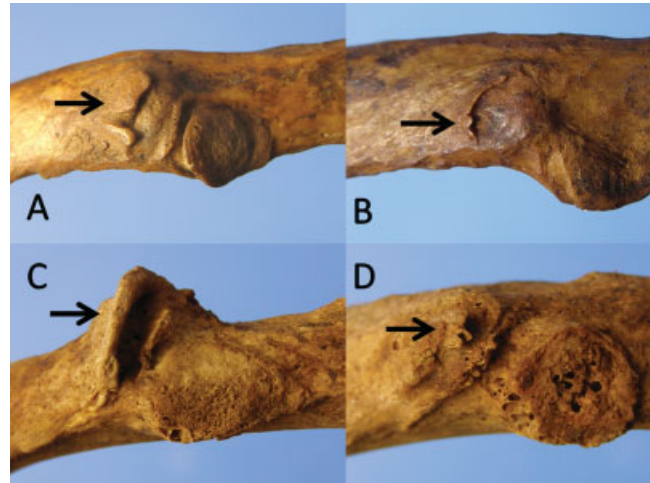


Fig. 6. **A:** The fourth left rib of a 19-year-old female. Observe the bony spur split in two portions that extend over the nonarticular tubercle from its lateral border. **B:** The sixth left rib of a 30-year-old male. Observe a similar bony spur that extends over the nonarticular tubercle. **C:** The fourth left rib of a 40-year-old male. Observe the prominent bony spur that extends over the non-articular tubercle. **D:** From the same individual as in C. Observe the subtle bony spur that extends over the nonarticular tubercle. [Color figure can be viewed in the online issue, which is available at www.interscience.wiley.com.]



Fig. 7. Three left ribs from a forensic case exhumed from an unmarked cemetery from Spain postwar (1938–1943). The articular tubercle of the rib on the left is scored as Stage 3, although the epiphysis does not cover the whole surface of the tubercle. The epiphyses of the other two ribs are scored as Stage 2, as it is easy to observe empty space underneath them. [Color figure can be viewed in the online issue, which is available at www.interscience.wiley.com.]

years of age (see Fig. 6). From our observations we would suggest that the main features of this bony spur are that it is thicker than the epiphysis, it usually grows from the outside of the tubercle, and its medial border is not as rounded and as regular as that of the epiphyses. This bony spur is also frequently split in two or more portions and, while the whole epiphysis is in close contact with the bone surface, the bony spur usually rises above the bone surface (see Fig. 6). Although Stages 1

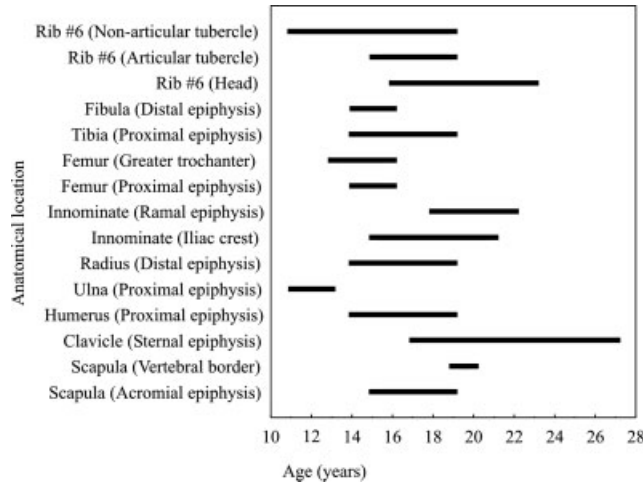


Fig. 8. Age ranges of fusion in the sixth and ninth rib epiphyses compared with the age ranges of fusion in a selection of epiphyses from the girdle and limb bones in females from the Lisbon collection.

and 3 are difficult to distinguish, we believe that Stage 2 is informative and in many cases its scoring can be unequivocal (see Fig. 2), despite the aforementioned bony spur (see Fig. 6).

As an illustration of the utility of observing Stage 2 at the tubercles, Figure 7 shows the articular tubercle of three ribs from a Spanish Civil War forensic archaeological case that has been already genetically identified. A presumptive identification was initially obtained from this skeleton based on the fact that this case presented the youngest biological age of the 114 skeletons exhumed from an unmarked prisoner's cemetery, for which names and ages at death of all the deceased persons were recorded in the civil and penitentiary archives. Among other immature features, this skeleton was the only one that presented partial union at the articular tubercles of the ribs. In this case, the age range assigned, based on the observation of Stage 2 at the articular tubercle of the ribs, would be 16–20 years (Table 7). The lower limit (16 years) correspond to the youngest cases with Stage 2 at any rib (Ribs 1, 4, 7, 8, and 10 in Table 7), while the upper limit (20 years) correspond to the oldest cases with Stage 2 at any rib (Rib 8 in Table 7). Although in this study ribs were identified (side and number), rib identification will be frequently precluded by poor preservation, so we recommend to assign an age range considering all the ribs. In this specific case from the Spanish Civil War, the age range obtained from the rib epiphyses would be narrower than for instance the age range of 16–21 years assigned from the stage of fusion of the proximal humerus, which was scored as active union (Cardoso, 2008b). Therefore, the presence of epiphyseal activity at the vertebral end of the ribs can be used to construct an age range, although the age ranges offered in Tables 6–8 are generally broader in comparison with the age ranges obtained from other bones from the same collection (Cardoso, 2008a,b). Figure 8 illustrates how the ranges of fusion in the sixth rib epiphyses compare with epiphyses from both girdles and limb bones in females from the Lisbon collection.

Our finding of earlier fusion of first and last ribs (Table 9) are in agreement with the observations of McKern

TABLE 10. Statistically significant sex differences for the head epiphysis, as assessed by the Mann-Whitney U test (u_{mw}) and Chi-square test (χ^2)

Age group Rib number	17–20 years			21–24 years	
	4	6	9	2	9
u_{mw}	556.500	493.500	415.000	99.000	63.500
P	0.027	0.037	0.018	0.042	0.033
χ^2	5.594	6.236	9.280	4.258	4.700
P	0.061	0.101	0.026	0.119	0.095

and Stewart for the epiphysis of the head of the ribs (1957), the observations about the fusion of the thoracic vertebral neurocentral junction (Scheuer and Black, 2000), and the observations on the thoracic vertebral epiphyseal rings (Albert and Maples, 1995). However, this trend is not as clear as that observed by McKern and Stewart (1957), probably because of their larger sample sizes for the different ages.

We found significant, but not consistent, sex differences in rib maturation. Females tend to show advanced union in all three epiphyses relative to males, but the statistical tests only confirmed this tendency for a limited number of ribs and for certain age groups (Tables 10–12). It can be seen that most of the sexual differences are centered in the epiphyses of the tubercles and in the younger age groups, especially in the early fusing non-articular tubercle, and this could reflect the earlier onset and shorter duration of puberty in females (Aksglaede et al., 2008). The sexual difference toward an earlier female maturation is consistent with other studies in which females present an earlier maturation than males (Albert and Maples, 1995; Veschi and Fachini, 2002; Coqueugnot and Weaver, 2007; Cardoso, 2008a,b; Ríos et al., 2008). It is also interesting to note that our results show broader age intervals for partial union of epiphyses in females (which encompass the male age interval), indicating a longer maturation period. This is in somewhat contradiction with the earlier and shorter maturation of females, but it may result from the small sample size and the cross-sectional nature of our sample. The problems of sample size and age distribution are permanent in subadult and young adult documented skeletal samples, so that it is difficult to properly address the issue of sexual differences in maturation, when large and equally distributed samples are not available. Therefore, we consider our sex differences results, for the most part, as tentative and compatible with those of previous research (Veschi and Fachini, 2002; Coqueugnot and Weaver, 2007; Cardoso, 2008a,b; Ríos et al., 2008). Besides sampling problems, we have found that one individual can have a large influence in establishing the age intervals. For example, in the head epiphysis one 23-year-old female was scored as Stage 1 on ribs number 10, 11, and 12. If we eliminate this case, the upper age limit of the interval changes from 23 to 19 years. This female died of pulmonary tuberculosis and lived in a low socioeconomic status neighborhood, suggesting the possibility that environmental factors can have some impact in establishing the age ranges.

The effects of environmental conditions, such as socioeconomic and nutritional status, on chronological age estimation from bones have recently received attention from different researchers working in skeletal maturation (Schmeling et al., 2000, 2006; Meijerman et al., 2007; Cardoso, 2007, 2008a,b), as well as in adult ageing

TABLE 11. Statistically significant sex differences for the articular tubercle epiphysis, as assessed by the Mann-Whitney U test (u_{mw}) and Chi-square test (χ^2)

Age group Rib number	11–16 years				17–20 years			
	1	3	8	9	5	6	7	8
u_{mw}	111.500	306.000	221.000	224.500	673.500	601.000	555.000	581.000
P	0.006	0.035	0.035	0.024	0.036	0.020	0.018	0.030
χ^2	8.204	5.712	5.183	5.527	4.782	6.081	5.680	5.342
P	0.017	0.057	0.075	0.063	0.092	0.108	0.058	0.069

TABLE 12. Statistically significant sex differences for the nonarticular tubercle epiphysis, as assessed by the Mann-Whitney U test (u_{mw}) and Chi-square test (χ^2)

Age group Rib number	11–16 years						17–20 years					
	2	3	4	5	6	7	8	4	5	6	7	8
u_{mw}	174.500	234.500	191.500	210.000	191.500	140.500	79.000	600.000	620.000	533.000	285.000	100.000
P	0.013	0.008	0.001	0.012	0.020	0.003	0.003	0.004	0.015	0.036	0.019	0.054
χ^2	7.347	7.651	11.809	8.259	5.519	9.519	11.960	8.324	5.947	5.006	5.643	6.682
P	0.062	0.054	0.003	0.016	0.063	0.009	0.003	0.016	0.051	0.171	0.060	0.035

techniques (Paine and Brenton, 2006). Working with large living samples, Schmelting et al. (2000, 2006) and Meijerman et al. (2007) state that the socioeconomic status of the samples, for instance as measured by the Human Development Index (Meijerman et al., 2007), has a significant impact on age estimation from the state of maturation of the wrist and clavicle. A delay of about 1 year in bone age can be expected in low socioeconomic status individuals (Frisancho et al., 1970a,b). Future research is clearly needed to estimate the impact of environmental factors (socioeconomic status, nutrition) on age estimation when working with pubertal and young adult skeletons. Given that fluctuating asymmetry has also been suggested to be indicative of environmental stress (Albert and Greene, 1999), we have examined the socioeconomic background of the asymmetric individuals against the symmetric group. On the basis of previously published data (Cardoso, 2005), our tentative analysis included parental occupation, place of residence, migration status (rural living, urban living, or rural-to-urban-migration), and cause of death. The symmetric and asymmetric groups differ in migration status. All 22 of the rural-to-urban migrants were asymmetric, while the 74 nonmigrants showed a more equal distribution of symmetry/asymmetry (40% symmetric, 60% asymmetric) (Chi-square = 11.0, $P < 0.001$). At the beginning of the twentieth century, migrating from rural areas to major cities (such as Lisbon), usually placed children and adolescents at a greater risk for malnutrition, disease, and even physically demanding working conditions (Bogin, 1988), with obvious impact on growth and maturation. This is related to the fact that urban migrants moved to the underprivileged areas of the city (such as slums), where living conditions were poor and unsanitary, much like rural-to-urban migrants in the modern third world (Islam and Azad, 2008). With regard to the cause of death, the difference in the frequency of chronic conditions was not significant. The relation of the socioeconomic background with the delay in bone age, and with the presence of asymmetry in the state of fusion, is a topic which deserves further research, and a full analysis is out of the scope of this article.

CONCLUSIONS

The epiphyses of the head, of the articular tubercle and of the nonarticular tubercle of the ribs are useful to estimate the age of subadult and young adult skeletons and only scarce information has been available. However, some caution is needed in scoring. The scoring of the stage of fusion of the tubercle epiphyses can be difficult, especially when trying to distinguish between absence of fusion and complete fusion, therefore, in those cases we recommend not to use the rib's tubercles for age estimation. However, we observed that in many cases scoring Stage 2 (active fusion) was a straight task at both tubercles, and this can be useful for age estimation between 11 and 20 years. Sex differences were observed toward an earlier female maturation, although this trend was confirmed only for some ribs and age groups. A significant number of cases presented fluctuating asymmetry between pairs of ribs. This could be related to the influence of environmental quality on maturation, but further research is needed to reach any sound conclusion in this regard.

ACKNOWLEDGMENTS

We are grateful to the editor and three anonymous reviewers for valuable comments. The research trypt to Lisbon of L.R. was supported by a grant from the Programa de Movilidad de Personal Joven Investigador from the Universidad Autónoma de Madrid.

LITERATURE CITED

- Aksglaede L, Olsen LW, Sørensen TIA, Juul A. 2008. Forty years trends in timing of pubertal growth spurt in 157,000 Danish school children. *PLoS ONE* 3:e2728.
- Albert AM, Maples WR. 1995. Stages of epiphyseal union for thoracic and lumbar vertebral centra as a method of age determination for teenage and young adult skeletons. *J Forensic Sci* 40:623–633.

- Albert AM, Greene DL. 1999. Bilateral asymmetry in skeletal growth and maturation as an indicator of environmental stress. *Am J Phys Anthropol* 110:341–349.
- Bogin B. 1988. Rural-to-urban migration. In: Mascie-Taylor CGN, Lasker GW, editors. *Biological aspects of human migration*. Cambridge: Cambridge University Press. p 90–129.
- Byers S. 2005. *An introduction to forensic anthropology: a textbook*. Boston: Pearson.
- Cardoso HFV. 2005. Patterns of growth and development of the human skeleton and dentition in relation to environmental quality. Ph.D. thesis. Hamilton, McMaster University.
- Cardoso HFV. 2006. Brief communication: the collection of identified human skeletons housed at the Bocage Museum (National Museum of Natural History). Lisbon, Portugal. *Am J Phys Anthropol* 129:173–176.
- Cardoso HFV. 2007. Environmental effects on skeletal versus dental development: using a documented subadult skeletal sample to test a basic assumption in human osteological research. *Am J Phys Anthropol* 132:223–233.
- Cardoso HFV. 2008a. Epiphyseal union at the innominate and lower limb in a modern Portuguese skeletal sample, and age estimation in adolescent and young adult male and female skeletons. *Am J Phys Anthropol* 135:161–170.
- Cardoso HF. 2008b. Age estimation of adolescent and young adult male and female skeletons II, epiphyseal union at the upper limb and scapular girdle in a modern Portuguese skeletal sample. *Am J Phys Anthropol* 137:97–105.
- Coqueugniot H, Weaver TD. 2007. Brief communication: infracranial maturation in the skeletal collection from Coimbra, Portugal: new aging standards for epiphyseal union. *Am J Phys Anthropol* 134:424–437.
- DiGangi EA, Bethard JD, Kimmerle EH, Konigsberg LW. 2009. A new method for estimating age-at-death from the first rib. *Am J Physical Anthropology* 138:164–176.
- Dudar JC. 1993. Identification of rib number and assessment of intercostal variation at the sternal rib end. *J Forensic Sci* 38:788–797.
- Fawcett E. 1911. Some notes on the epiphyses of the ribs. *J Anat Physiol* 45:172–178.
- Frisancho AR, Garn SM, Ascoli W. 1970a. Unequal influence of low dietary intakes on skeletal maturation during childhood and adolescence. *Am J Clin Nutr* 23:1220–1227.
- Frisancho AR, Garn SM, Ascoli W. 1970b. Childhood retardation resulting in reduction of adult body size due to lesser adolescent skeletal delay. *Am J Phys Anthropol* 33:325–336.
- Hodges PC. 1933. An epiphyseal chart. *Am J Roentgenol* 30:809–810.
- Hoppa R, Saunders S. 1998. Two quantitative methods for rib seriation in human skeletal remains. *J Forensic Sci* 43:174–177.
- Hoppa RD, Vaupel JW. 2002. *Paleodemography: age distributions from skeletal samples*. Cambridge: Cambridge University Press.
- Hoppenfeld S, Lonner B, Murthy V, Gu Y. 2004. The rib epiphysis and other growth centers as indicators of the end of spinal growth. *Spine* 29:47–50.
- Ibrahim AF, Darwish HH. 2005. The costotransverse ligaments in human: a detailed anatomical study. *Clin Anat* 18:340–345.
- Iscan MY. 1989. *Age markers in the human skeleton*. Springfield: Charles C. Thomas Publisher.
- Iscan MY, Loth SR, Wright RK. 1984. Age estimation from the rib by phase analysis: white males. *J Forensic Sci* 29:1094–1104.
- Iscan MY, Loth SR, Wright RK. 1985. Age estimation from the rib by phase analysis: white females. *J Forensic Sci* 30:853–863.
- Islam MM, Azad KM. 2008. Rural-urban migration and child survival in urban Bangladesh: are the urban migrants and poor disadvantaged? *J Biosoc Sci* 40:83–96.
- Kimmerle EH, Prince DA, Berg GE. 2008. Inter-observer variation in methodologies involving the pubic symphysis, sternal ribs, and teeth. *J Forensic Sci* 53:594–600.
- Kunos CA, Simpson SW, Russell KF, Hershkovitz I. 1999. First rib metamorphosis: its possible utility for human age-at-death estimation. *Am J Phys Anthropol* 110:303–323.
- Kurki H. 2005. Use of the first rib for adult age estimation: a test of one method. *Int J Osteoarchaeol* 15:342–350.
- Loth SR. 1995. Age assessment of the Spitalfields cemetery population by rib phase analysis. *Am J Hum Biol* 7:465–471.
- Mann RW. 1993. A method for siding and sequencing human ribs. *J Forensic Sci* 38:151–155.
- Martrille L, Ubelaker DH, Cattaneo C, Seguret F, Tremblay M, Baccino E. 2007. Comparison of four skeletal methods for the estimation of age at death on white and black adults. *J Forensic Sci* 52:302–307.
- Mays S. 1998. *The archaeology of human bones*. New York: Routledge.
- McKern TW, Stewart TD. 1957. Skeletal changes in young American males. Analyzed from the standpoint of age identification. Environmental Protection Research Division (U.S. Army Quartermaster Research and Development Command), Technical Report EP-45. Natick, US Army.
- Meijerman L, Maat GJR, Schulz R, Schmeling A. 2007. Variables affecting the probability of complete fusion of the medial clavicular epiphysis. *Int J Leg Med* 121:463–468.
- Oettlé AC, Steyn M. 2000. Age estimation from sternal end of ribs by phase analysis in South African blacks. *J Forensic Sci* 45:1071–1079.
- Owers SK, Pastor SF. 2005. Analysis of quantitative methods for rib seriation using the Spitalfields documented skeletal collection. *Am J Phys Anthropol* 127:210–218.
- Paine RR, Brenton BP. 2006. Dietary health does affect histological age assessment: an evaluation of the Stout and Paine (1992) age estimation equation using secondary osteons from the rib. *J Forensic Sci* 51:489–492.
- Rios L, Weisensee K, Rissech C. 2008. Sacral fusion as an aid in age estimation. *Forensic Sci Int* 180:111–117.
- Schaefer MC, Black SM. 2005. Comparison of ages of epiphyseal union in North American and Bosnian skeletal material. *J Forensic Sci* 50:777–784.
- Scheuer L, Black S. 2000. *Developmental juvenile osteology*. London: Academic Press.
- Schmeling A, Reisinger W, Loreck D, Vendura K, Markus W, Geserick G. 2000. Effects of ethnicity on skeletal maturation: consequences for forensic age estimations. *Int J Legal Med* 113:253–258.
- Schmeling A, Schulz R, Danner B, Rosing FW. 2006. The impact of economic progress and modernization in medicine on the ossification of hand and wrist. *Int J Legal Med* 120:121–126.
- Schmeling A, Geserick G, Reisinger W, Olze A. 2007. Age estimation. *Forensic Sci Int* 165:178–181.
- Schmitt A, Murail P. 2004. Is the first rib a reliable indicator of age at death assessment? Test of the method developed by Kunos et al. 1999. *Homo* 54:207–214.
- Standring S. 2005. *Gray's anatomy: the anatomical basis of clinical practice*. London: Elsevier Churchill Livingstone.
- Stevenson PH. 1924. Age order of epiphyseal union in man. *Am J Phys Anthropol* 7:53–93.
- Veschi S, Facchini F. 2002. Recherches sur la collection d'enfants et d'adolescents d'âge et de sexe connus de Bologne (Italie): diagnose de l'âge sur la base du degré de maturation osseuse. *Bulletins et Mémoires de la Société d'Anthropologie de Paris* 14:263–294.
- Wittwer-Backofen U, Buckberry J, Czarnetzki A, Doppler S, Grupe G, Hotz G, Kemkes A, Larsen CS, Prince D, Wahl J, Fabig A, Weise S. 2008. Basics in paleodemography: a comparison of age indicators applied to the early medieval skeletal sample of Lauchheim. *Am J Phys Anthropol* 137:384–396.
- Yavuz MF, Iscan MY, Cologlu AS. 1998. Age assessment by rib phase analysis in Turks. *Forensic Sci Int* 98:47–54.